



The Work-Up

Diagnostic Services Unit | Issue 6 - March/April, 2023

Inside this Issue:

SPECIAL EDITION: Parasites

Spotlight: Sara Skotarek Loch and Sam Lewin

Deworming in grazing animals

Heterakis gallinarum in poultry

Nervous Coccidiosis in feedlot cattle

Microfilaria and Aspergillosis in a Northern Hawk Owl

Tips & Tricks: Ovine parasites

DSU Announcements

Congratulations to the DSU Bacteriology Lab for winning the inaugural UCVM Award's Night Team Award!

Congratulations to Dr. Angelica Galezowski for winning the SCV-MA Teacher of the Year Award!

Welcome Ciara O'Higgins, the DSU's newest Ancillary Services Technician!

A big thanks to Nancy Coulter in her role as Histology Technician over the last few months. Her last day was February 28 and we wish her the best as she takes some time with her family. We hope to see her back here supporting the DSU soon!


Holiday Closures:
Easter: Friday April 7 to Monday April 10, 2023

SPOTLIGHT

Sara Skotarek Loch began studying horse parasites as part of an undergraduate research project at Vancouver Island University. Her love of horses and fascination with parasitology lead her to combine these interests and she completed an honours project and BSc in Biology. In 2008, she completed her MSc at the University of Lethbridge investigating prevalence of and diagnostic assays for horse tapeworms. Sara joined UCVM researching heaves in horses and shortly after took a permanent position organizing and teaching anatomy labs, and then pathology and parasitology labs for the vet students. In 2022 she took the role of Operations Manager for the Diagnostic Services Unit, and is excited about the mission to advance education, research and scholarly programs through the expansion of the DSU.



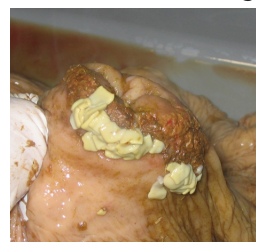Sam Lewin obtained her Hospital Unit Clerk Certificate in 2017. With a strong passion for animals and medicine she started her career at the University of Calgary as an Administrative Assistant in the Faculty of Veterinary Medicine in March 2017. Sam is currently the Administrative Assistant for the DSU and is vital to the day to day functioning of the lab. She has been involved in many aspects of UCVM including faculty assistance, summer camps, and special event planning but Sam's special passion is reindeer husbandry and research with the UCVM herd.



PC: Sam Lewin

Deworming has always been a vital part of the health care plan in grazing animals. Regular interval rotational deworming introduced in the 1960s has fueled growing parasite resistance to dewormers. Worms were naïve to the drugs and the goal was to kill the worms before they could mature and lay eggs to contaminate the environment. All grazing animals have parasites, but infection is not the same as disease. These animals have evolved in the presence of parasites and have different strategies to cope, the problem lies in the animals over-burdened with worms or more susceptible to infection. Decades of frequent treatment has selected for drug-resistant worms in ruminants and horses, emphasizing that traditional

approaches for parasite control are not sustainable. Effective parasite control now involves more than just alternating products, but also using different classes of dewormers for effectiveness to mitigate further resistance issues. Ideally, better grazing management combined with targeted treatment strategies are implemented together. This rise in resistant parasites means that veterinarians play a crucial role in educating producers and owners about diagnosis and targeted treatment of their animals.



Article and photo courtesy of Sara Skotarek Loch

The Work-Up

Diagnostic Services Unit

Issue 6 - 2023

DSU Team

Anatomic Pathologists:

Dr. Jennifer Davies
Dr. Dayna Goldsmith
Dr. Ashish Gupta
Dr. Cameron Knight
Dr. Carolyn Legge
Dr. Jamie Rothenburger
Dr. Amy Warren
Dr. Erin Zachar

Clinical Pathologists:

Dr. Angelica Galezowski
Dr. Catherine Wagg
Dr. Amy Warren

Microbiologist:

Dr. Beverly Morrison

Support Staff:

Jim Carlsen
Makaela Douglas
Mai Farghaly
Karan Gadani
Lori Goodbrand
Jennifer Larios
Samantha Lewin
Heather Mitchell-Matheson
Mel Nicolas
Ciara O'Higgins
Dr. Lindsay Rogers
Sara Skotarek Loch

DSU Contact Information

<https://vet.ucalgary.ca/DSU>

E-mail: dsu@ucalgary.ca

Phone: 403-220-2806

Fax: 403-239-6984

Clinical Skills Building
11877 85th Street NW
Calgary AB, T3R 1J3

Heterakis gallinarum were found in the ceca of 48-week-old broiler breeders submitted for necropsy exam. The incidence of cecal worms in broiler breeders is increasing in North America. *H. gallinarum* eggs carry the protozoa, *Histomonas meleagridis*, the causative agent of black head in turkeys. Black head can cause up to 100% mortality in a turkey flocks making control of *H. gallinarum* in chickens important to minimize the



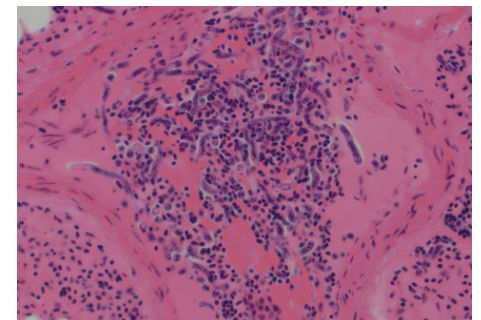
Ceca containing *H. gallinarum* worms (PC: Mel Nicolas)

spread of histomoniasis to commercial turkey flocks. The worms also compete for nutrients and may contribute to reduced egg production in chickens.

Nervous coccidiosis was the suspected cause of neurological signs in feedlot cattle that were approximately 30 days on feed. On histopathology, changes in the colon were consistent with coccidiosis and there were no microscopic lesions in the brain. This suggested nervous coccidiosis was responsible for the observed nervous signs. Coccidiosis, a common protozoan disease of cattle caused by *Eimeria spp.*, usually leads to diarrhea and poor doing in cattle 3 weeks to 6 months of age. It has been observed to cause neurologic signs, usually coinciding with the movement of recently weaned calves into feedlots. The pathogenesis is not fully elucidated, and diagnosis is made with a combination of history and response to treatment, clinical exam, necropsy, and laboratory tests. Mesocolonic edema and/or hemorrhagic content in the colon can

be observed on gross exam. Nervous coccidiosis does not cause gross or microscopic lesions in the brain; therefore, the diagnosis cannot be made by examination of the brain alone. Identification of the parasite in feces or in the colon in combination with an absence of brain lesions is key to the diagnosis.

Fungal disease and parasitism were found in a wild Northern Hawk Owl submitted for necropsy for suspected highly pathogenic avian influenza (HPAI) as it lacked stamina and maneuverability in flight. On gross exam, the owl had severe consolidation of the right lung with granulomas due to a severe acute Aspergillosis. Histology revealed high numbers of microfilariae throughout its vasculature, especially in the lungs. Necrosis and inflammation were present in the brain secondary to either the microfilaria or fungal infection. Evidence of other parasitic infections was present including granulomatous inflammation in the small intestine (suspect trematode eggs), *Capillaria* species within the esophagus, and incidental sarcocysts within the heart. Microfilariae are typically non-pathogenic in wild birds but have been rarely reported to contribute to mortality as was likely in this case. The bird tested negative for HPAI.



Microfilaria in blood vessels (PC: Dayna Goldsmith)

Tips & Tricks: Ovine Parasitic Gastroenteritis and Haemonchosis Alert

It is important to monitor ewe fecal egg counts in the spring to assess likely pasture contamination and parasitic disease risk later in the season. *Haemonchus contortus*, a common cause of anaemia and even mortality, is generally resistant to ivermectin and fenbendazole/albendazole drugs in western Canada and so is not well controlled by these products. Closantel, the only effective drug currently available in Canada, should be judiciously used using risk assessment and targeted selective treatment principals. For further information see <https://vet.ucalgary.ca/research/sheep-parasite-control/home>. Courtesy of Dr. John Gilleard



Haemonchus contortus worms (PC: Paul Gajda)

